



## Cosmeceutical effect of ethyl acetate fraction of Kombucha tea by intradermal administration in the skin of aged mice.

Pakravan N<sup>1</sup>, Mahmoudi E<sup>2</sup>, Hashemi SA<sup>3</sup>, Kamali J<sup>4</sup>, Hajiaghayi R<sup>5</sup>, Rahimzadeh M<sup>6</sup>, Mahmoudi V<sup>7</sup>.

### Author information

- 1 Division of Immunology, Medical School, Alborz University of Medical Sciences, Karaj, Iran.
- 2 Department of Parasitology and Mycology, Medical School, Alborz University of Medical Sciences, Karaj, Iran.
- 3 Department of Pathology, Medical School, Alborz University of Medical Sciences, Karaj, Iran.
- 4 Department of Operating Room Nursing, Paramedical School, Alborz University of Medical Sciences, Karaj, Iran.
- 5 Herbal Medicine Research Center, Institute of Medicinal Plant, ACECR, Karaj, Iran.
- 6 Health, Safety, and Environment Research Center, Alborz University of Medical Sciences, Karaj, Iran.
- 7 Department of Food **Science** and Technology, Faculty of Agriculture, Islamic Azad University, Shahrekord, Iran.


### Abstract

**BACKGROUND/PURPOSE:** Natural ingredients have been always an interesting approach to prolong youthful appearance of skin. One of the natural compounds is Kombucha tea (KT), which has been mainly used as an energy drink in Asian countries for a long time. Previous reports indicated that it has pharmaceutical and favorable wound repairing effects. The beneficial properties of KT are thought to be mainly due to the presence of fermentation products such as flavonoids and other polyphenols with inhibition of hydrolytic and oxidative enzymes and anti-inflammatory effects. These properties prompted us to study the anti-aging potential of KT and investigate its effective fraction in aged mice, **METHODS:** Kombucha tea was fractionated into chloroform, butanol, and ethyl acetate, and flavonoid content was determined. Young and old mice were used as control. KT ethyl acetate fraction (KEAf), which had the highest flavonoid content, was intradermally administered to old mice.

**RESULTS:** Administration of KEAf significantly increased the collagen content, NAD<sup>+</sup> /NADH level, and concomitantly improved skin connective tissue abnormalities in the aged skin. No sensitivity or irritation was observed.

**CONCLUSION:** This finding suggested that KEAf can be a suitable candidate as a cosmetic product to improve aging-related skin abnormalities and regeneration of aged skin.

# Cosmeceutical effect of ethyl acetate fraction of Kombucha tea by intradermal administration in the skin of aged mice

Nafiseh Pakravan PhD<sup>1</sup>  | Elaheh Mahmoudi PhD<sup>2</sup> | Seyed-Ali Hashemi PhD<sup>3</sup> |  
Jamal Kamali BSc<sup>4</sup> | Reza Hajiaghayi PhD<sup>5</sup> | Mitra Rahimzadeh PhD<sup>6</sup> |  
Vajiheh Mahmoodi MSc<sup>7</sup>

<sup>1</sup>Division of Immunology, Medical School, Alborz University of Medical Sciences, Karaj, Iran

<sup>2</sup>Department of Parasitology and Mycology, Medical School, Alborz University of Medical Sciences, Karaj, Iran

<sup>3</sup>Department of Pathology, Medical School, Alborz University of Medical Sciences, Karaj, Iran

<sup>4</sup>Department of Operating Room Nursing, Paramedical School, Alborz University of Medical Sciences, Karaj, Iran

<sup>5</sup>Herbal Medicine Research Center, Institute of Medicinal Plant, ACECR, Karaj, Iran

<sup>6</sup>Health, Safety, and Environment Research Center, Alborz University of Medical Sciences, Karaj, Iran

<sup>7</sup>Department of Food Science and Technology, Faculty of Agriculture, Islamic Azad University, Shahrekord, Iran

## Correspondence

Elahe Mahmoudi, Department of Parasitology and Mycology, Medical School, Alborz University of Medical Sciences, Karaj, Iran.

Email: e\_m592000@yahoo.com

## Funding information

Deputy of Research, Alborz University of Medical Sciences

## Summary

**Background/purpose:** Natural ingredients have been always an interesting approach to prolong youthful appearance of skin. One of the natural compounds is Kombucha tea (KT), which has been mainly used as an energy drink in Asian countries for a long time. Previous reports indicated that it has pharmaceutical and favorable wound repairing effects. The beneficial properties of KT are thought to be mainly due to the presence of fermentation products such as flavonoids and other polyphenols with inhibition of hydrolytic and oxidative enzymes and anti-inflammatory effects. These properties prompted us to study the anti-aging potential of KT and investigate its effective fraction in aged mice.

**Methods:** Kombucha tea was fractionated into chloroform, butanol, and ethyl acetate, and flavonoid content was determined. Young and old mice were used as control. KT ethyl acetate fraction (KEAf), which had the highest flavonoid content, was intradermally administered to old mice.

**Results:** Administration of KEAf significantly increased the collagen content, NAD<sup>+</sup>/NADH level, and concomitantly improved skin connective tissue abnormalities in the aged skin. No sensitivity or irritation was observed.

**Conclusion:** This finding suggested that KEAf can be a suitable candidate as a cosmetic product to improve aging-related skin abnormalities and regeneration of aged skin.

## KEYWORDS

aging, collagen, ethyl acetate fraction, Kombucha tea, NAD<sup>+</sup>/NADH

## 1 | INTRODUCTION

Skin aging is a biological process during which changes in the structural integrity and physiological function of skin are induced. Visible sign of aging includes development of dyschromia, roughness, fine wrinkles followed by persistent deeper folds.<sup>1-3</sup> These changes occur following microscopic structural changes including epidermal thinning, dermal atrophy, reduction in connective tissue, decreased numbers of keratinocytes, reduced levels of elastin and collagen

synthesis, increased level of collagenase/matrix metalloproteinase (MMP), increased oxidants,<sup>2-4</sup> reduction in the number and size of vascular vessels,<sup>5</sup> loss of subcutaneous fat and elasticity, and increased melanogen.<sup>6</sup> Thinning and loss of collagen fibers, which form 90% of wet weight of skin connective tissue, are other prominent features of aging skin.<sup>7,8</sup>

Anti-aging products are used to protect skin against aging process. These agents are capable of protecting the skin matrix by inhibition of enzymatic degradation or promotion of collagen synthesis

in the skin.<sup>8-10</sup> Several efforts have been made to replace synthetic anti-aging agents with natural alternatives. Of particular interest is the use of traditional foods and medicines containing active ingredients.<sup>11-14</sup> One of these natural compounds is Kombucha tea (KT). This so-called long-life mushroom tea has been known as popular natural remedy for a long time and mainly used as an energy drink in Asian countries. It is prepared from the fermentation of sugared black tea (BT) with a symbiotic culture of acetic bacteria and *Kombucha* fungi.<sup>14,15</sup> Previous reports indicated that Kombucha has valuable cosmetic activities when applied topically. Kombucha specifically fights against glycation and the various gaps of skin metabolism leading to improvement in the aging signs and cutaneous microrelief.<sup>16,17</sup> The beneficial properties of KT are thought to be due to the presence of vitamins, amino acids, and a variety of micronutrients produced during fermentation. KT is especially a good source of flavonoid and vitamin B3.<sup>18-20</sup> Flavonoids are important anti-aging components that their amount in KT is much more than BT.<sup>21</sup> They are a group of polyphenolic compounds with free radical scavenging, inhibition of hydrolytic and oxidative enzymes, and anti-inflammatory activities and capable of physically blocking UV penetration, influencing DNA repair, and induction of cytoprotective pathways in skin.<sup>21-25</sup> Vitamin B3 is a precursor of nicotinamide adenine dinucleotide (NAD), which declines during aging leading to reduction in collagen expression within cells.<sup>21-23</sup>

Apart from cosmeceutical effects of KT, it has also been claimed to have pharmaceutical effects and favorable wound repairing effects when applied topically.<sup>18-20</sup> However, there are reports attributing side effects to this beverage<sup>26</sup> and specifically, to date no report has determined the effective fraction of KT. To reduce possible side effects, determination of the effective anti-aging fraction of KT can be beneficial. To do so, in this study KT was fractionated using organic solvents and the effective anti-aging fraction was determined.

## 2 | MATERIALS AND METHODS

### 2.1 | BT and KT preparation

Black tea (Golestan, Tehran, Iran) was added to boiling water (1.2% w/v), mixed, and left to brew for 5 minutes. The tea was then filtered through a sterile sieve, and sucrose (10%) was dissolved in the tea. To prepare KT, 200 mL of the cooled BT was inoculated with 3% w/v tea fungus plus 10% v/v previously fermented KT liquid and left to ferment by incubating the *Kombucha* culture at 28°C for 14 days. The resultant fermented tea was centrifuged at 600 g for 20 minutes.<sup>19</sup>

### 2.2 | Fractionation of KT

According to the method defined by Jayabalan,<sup>19</sup> 3 fractions of KT including KCf (Kombucha tea chloroform fraction), KBf (Kombucha tea butanol fraction), and KEAf (Kombucha tea ethyl acetate fraction) (1/2 v/v) were concentrated using a vacuum rotary evaporator (R-200 model of Buchi, Sigma-Aldrich, Taufkirchen, Germany). This process led to preparation of a viscid mass, which was dissolved in distilled

water, filtered through 0.22- $\mu$  Millipore membrane filter, lyophilized, and stored at -20°C.

### 2.3 | Content of total flavonoids in BT and KT fractions

The aluminum chloride colorimetric method was used to calculate the content of flavonoids.<sup>27</sup> Briefly, 1 mL (100 mg/mL) solution of each of BT, KT, KEAf, KCf, and KBf was mixed with 3 mL methanol, 0.2 mL of 10% aluminum chloride, 0.2 mL potassium acetate (1 mol/L), 5.6 mL of distilled water and incubated for 30 minutes at room temperature. Quercetin (Sigma-Aldrich, Taufkirchen, Germany) was prepared in dilutions of methanol (250-1000  $\mu$ g/mL) and used to prepare standard curve using spectrophotometry at a wave length of 415 nm. Total content of flavonoid compound ( $\mu$ g of QE/mg sample) was calculated by the formula:  $T = (C \times V)/M$ , C = concentration of quercetin (mg/mL), V = volume of solution (mL), M = weight of methanolic extract (gr). KEAf had the highest flavonoid content and was further used to test for its anti-aging effect.

### 2.4 | Experimental groups and study design

A total of 54 female NMRI mice were purchased from Pasteur Institute Experimental Animal Center (Tehran, Iran). All animals were kept under standard conditions of temperature ( $23 \pm 2^\circ\text{C}$ ) and humidity ( $50\% \pm 10\%$ ) with an alternating 12-h light/dark cycles at the conventional animal house of Alborz University of Medical Sciences. Given free access to food and water, mice were housed for 1 week before experiments and maintained under standard environmental conditions. All experiments were done according to Animal Care and Use Protocol of Ethics Committee of Alborz University of Medical Sciences.

According to the age, 5 experimental groups ( $n = 9$ ) were considered including: Group 1 as control young group (aged 2 months), Group 2 as old group (aged 15 months) treated with KEAf at a dose of 5 mg/mL, Group 3 as old group (aged 15 months) treated with KEAf at a dose of 10 mg/mL, Group 4 as control old group (aged 15 months) treated with saline, and Group 5 as control old group (aged 15 months) without any treatment. Treatments were carried out for 14 days and performed via the intradermal route after the induction of anesthesia and shaving a  $2 \times 2$  cm region behind the animal's neck.

### 2.5 | Evaluation of skin irritation

Each animal was examined visually for signs of skin reactions, such as erythema and edema, approximately 24 and 72 hours after intradermal injection.<sup>28</sup> Also, pathological damage such as inflammatory cell infiltration and fibroplasias was evaluated in hematoxylin and eosin (H&E)-stained sections.

### 2.6 | Histological analysis

To perform histological evaluation of the skin, the animals were sacrificed under ether anesthesia 72 hours after the last injection. Skin

tissue samples, including epidermis, dermis, were taken using a scalpel No. 15. The skin samples from the control and test groups were fixed in 10% buffered formalin and were processed for paraffin sectioning. Sections of about 3  $\mu\text{m}$  thickness were taken and stained with H&E. To further assess the amount of total collagen, skin samples were stained with Masson's trichrome. The stained sections were examined with an Olympus cX41 microscope, (Olympus, Tokyo, Japan), and photographed using an Olympus D330 digital camera. The photographs were analyzed via Scion Image Software to analyze markers of skin tissue alteration such as fiber length and width, fiber fragmentation, number of fibroblasts, and the space between fiber bundles of dermal connective tissue.

## 2.7 | Evaluation of total collagen content

The content of hydroxyproline was measured according to the method previously described by Kivirikko et al,<sup>29</sup> with some modifications. The skin tissue samples (0.3 g) were homogenized and hydrolyzed in 6 mol/L HCl, at 105°C for 16 hours. Free hydroxyproline was oxidized using chloramine T. Then, Ehrlich's reagent was added and incubated at 60°C leading to formation of a chromophore. Hydroxyproline product was further purified through extraction of interfering chromophores with toluene and then acid phase. The absorbance of the supernatant containing hydroxyproline was measured by spectrophotometry at the wavelength of 543 nm. Hydroxyproline content was calculated from the standard curve, which was linear at 10-160  $\mu\text{g}/\text{mL}$ .

## 2.8 | Immunohistochemical evaluation of collagen type I and III

Tissue sections of the skin samples were stained using antibody specific for collagen type I (1:100; Col 1A SC-59772, Santa Cruz, CA, USA) and anti-collagen III antibody (Sigma-Aldrich, Taufkirchen, Germany) as DAKO kit (Denmark). Anti-rabbit IgG antibody was used as secondary antibody, and the images were captured using a Zeiss LSM 5, (Carl Zeiss, Tokyo, Japan) fluorescent microscope. Paraffin sections obtained from each group were dewaxed and hydrated. Sections of 4  $\mu\text{m}$  were prepared from each sample, washed with PBS, incubated in 3%  $\text{H}_2\text{O}_2$  for 20 minutes, washed once more with PBS, and then incubated in a protein block solution for 10 minutes. Then, primary antibody (diluted 1:100 in 0.01 mol/L PBS) was added to sections and incubated for 1 hour, washed 3 times, and incubated with envision solution (complex of secondary antibody diluted 1:200 in PBS, avidin, and horseradish peroxidase). After 30-min incubation time, the enzyme activity was visualized using 3, 3'-diaminobenzidine (DAB). A brown staining was regarded as a positive reaction. Data are presented as the mean of 3 randomly selected fields of microscopic view.

## 2.9 | NAD<sup>+</sup> and NADH content

The content of dinucleotides NAD<sup>+</sup> and NADH was determined in skin tissue samples using NAD<sup>+</sup>/NADH assay kit (Abcam, London,

UK), according to the manufacturer's instructions. Briefly, about 20 mg of tissue sample was washed with cold PBS and homogenized with NAD/NADH extraction buffer. The supernatant was split into 2 aliquots. For NADH detection, the aliquot was incubated at 60°C for 30 minutes as NAD needs to be decomposed before the reaction. To determine NADt (NAD and NADH), the other aliquot was kept on ice to preserve NAD and NADH. The samples were transferred into 96-well plates, and then a mixture of NAD cycling enzyme/buffer was added to each sample. Finally, NADH developer was added to each reaction. NADH standard was prepared according to the manufacturer's instructions. Total NAD (NADt) and NADH were estimated directly, whereas the value of NAD<sup>+</sup> was estimated by subtracting NADH from NADt and expressed as pmol/ $\mu\text{g}$  of skin tissue.

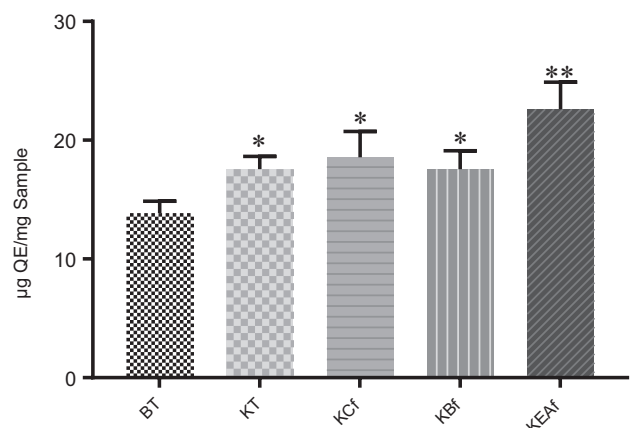
## 2.10 | Statistical analysis

Statistical analysis was performed using GraphPad Prism 7.01. Data are presented as means  $\pm$  SD. ANOVA was used to indicate any significant difference among the groups. Value of *P* was considered statistically significant when it was less than .05.

## 3 | RESULTS

### 3.1 | Flavonoid composition of BT, KT, and KT fractions

Total flavonoid content of each of BT, KT, KEAf, KCf, and KBf is shown in Figure 1. The flavonoid content increased in BT after fermentation by Kombucha culture. The rate of flavonoid concentration in KT and its derivatives was about 21%, 38.7%, 21%, and 25.4% in KT, KEAf, KBf, and KCf, respectively. As Figure 1 shows, concentration of flavonoid in KEAf is about 22.3% more than KT. As KEAf had the highest flavonoid content, it was further tested for anti-aging effect.



**FIGURE 1** Total flavonoid content of each sample ( $\mu\text{g}$  QE/100mg); the flavonoid concentrations significantly increased in Kombucha tea rather than unfermented black tea (BT). \**P* < .05 vs BT, \*\**P* < .007 vs BT

**TABLE 1** Evaluation of skin irritation in Kombucha tea ethyl acetate fraction (KEAf)- and PBS-treated animals; total score/number of mice (n = 9) = Ms

Groups Hours	Vehicle L (PBS)				KEAf			
	24		72		24		72	
Skin reaction	Erythema	Edema	Erythema	Edema	Erythema	Edema	Erythema	Edema
Mean score (Ms)	0	0.1	0	0	0	0	0	0

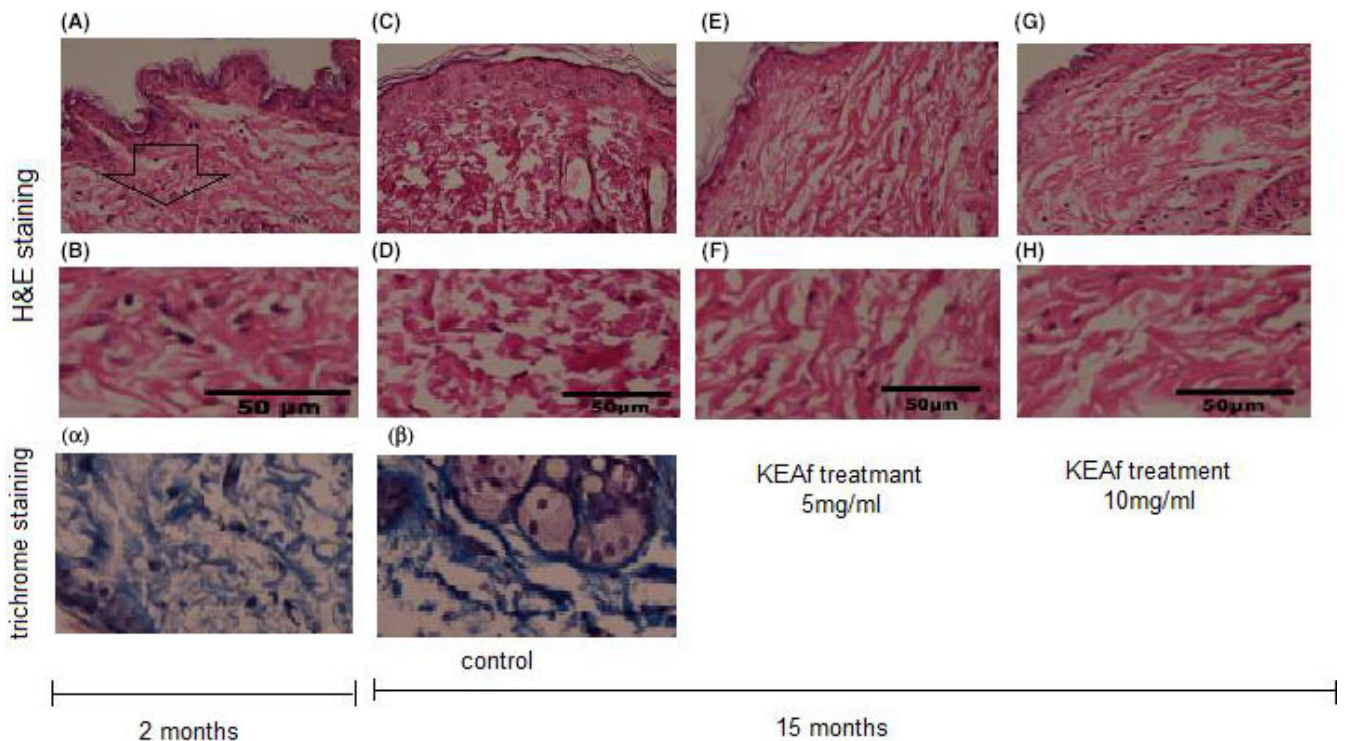
### 3.2 | Skin irritation assessment

Visual evaluation of skin reaction at 24 and 72 hours after ID injection did not show inflammatory reactions, such as edema and erythema. The score of irritation in KEAf and PBS groups was 0%, and the mean evaluation score was 0 (Table 1). Also, histological observation of the skin tissue sections did not show pathological damage or accumulation of inflammatory cells in the treated animals (Figure 2) suggesting that KEAf is not cytotoxic and does not sensitize the skin.

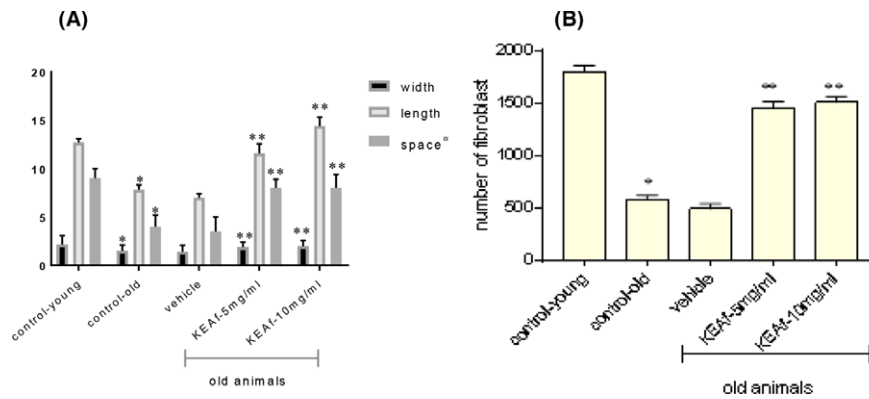
### 3.3 | Histological observation

Histological view of H&E- and trichrome-stained skin tissue of mice aged 2 and 15 months showed that age increment extends skin

tissue abnormalities represented as reduced fiber bundles width and length, increased space between dermal connective fiber bundles ( $P < .05$ , Figure 3A), and decreased numbers of fibroblasts ( $P < .05$ , Figure 3B). Also, decreased number of the collagen bundles in the upper layer of dermis, epidermal atrophy, and decreased interdigitation between the epidermis and dermis were seen in old skin tissue vs young samples (Figure 2). In the mice aged 2 months, the fibers formed a fibrous network and were less regularly arranged compare with in the older animals. Degrees of skin connective tissue abnormalities were significantly improved in samples treated with KEAf. Figures 2 and 3 together show that treatment with KEAf on average decreased skin connective tissue abnormalities approximately 48.2% in aged skin sample (15 month at age) vs vehicle-treated old skin ( $P < .007$ ). There was no significant difference between samples treated with 5 or 10 mg/mL KEAf.



**FIGURE 2** Formalin-fixed skin sections were stained with H&E and trichrome. (A) control 2-months old, (B) focus on (A), (C) control 15-months old, (D) focus on (C), (D) 15-months old mice treated with 5mg/ml KEAf, (E) focus on (D), (F) 15-months old mice treated with 5mg/ml KEAf, (E) focus on (F), (alpha) Trichrom staining of 2-months old, and (beta) trichrom staining of 15-months old control mice skin. Mice aged 15 months showed significant increase in abnormalities in connective tissue structure: thin, disorganized fiber bundles present throughout the dermis, and reduced numbers of fibroblasts. Also, patches of ground substance deposition increased in areas resembling degraded fiber bundles. Skin connective tissue alterations due to age increment are partially improved by KEAf treatment. Data is presented as the mean of three randomly selected fields of microscopic view. (Scale bar 50  $\mu$ m).



**FIGURE 3** (A) Average of skin connective tissue abnormalities was measured with an image analysis (image J: [imagej.nih.gov/ij/](http://imagej.nih.gov/ij/)). <sup>a</sup>space between dermal connective fiber bundles was scored using a scale of 1-10. (B) Number of fibroblast, per unit area: about 0.5 mm<sup>2</sup> per skin tissue sample. Correlation analysis between the numbers of fibroblasts in the dermis and age revealed a significant effect of age increment on the decrease of fibroblasts in the dermis. The amount of abnormalities decreased significantly with KEAf treatment. Values are means of 9 measurements. \**P* < 0.05 vs. 2 month-old mice, \*\**P* < 0.007 vs. vehicle-treated skin.

### 3.4 | KEAf stimulated type I and III collagen synthesis in the skin

Based on hydroxyproline estimation, the total collagen content was different in the skin tissue of the 2 different age groups. The aged skin tissue samples showed a mean reduction of 35.5% in hydroxyproline content comparing to the young skin tissue samples (*P* < .05, Table 2). Treatment with KEAf led to a 31.8% increase at the hydroxyproline content of the skin connective tissue samples of the old animals compared with those treated with PBS (*P* < .007, Table 2). Immunohistochemical staining of the skin from old and young animals with monoclonal antibody against collagen type I revealed that type I collagen content decreased in the aged skin compared to the skin tissue from young mice (Figure 4A). Analysis of the images by Image Scan software showed that there is about 29.3% lower collagen type I in the skin tissue samples from old animals than the young animals (*P* < .05, Figure 4B). However, immunohistochemical staining of collagen type III showed no prominent change in the skin connective tissue in mice aged 15 months (Figure 5). Based on hydroxyproline content and immunohistochemical analysis of collagen type I, KEAf treatment restored abnormalities (Figure 2), and increased total collagen in the skin of aged mice (Table 2). Intradermal treatment of skin of aged mice with KEAf revealed a significantly higher content of collagen type I and III compared with that of the vehicle group (Figures 4 and 5).

### 3.5 | NAD<sup>+</sup>/NADH content

In the final set of experiments, level of NAD<sup>+</sup>/NADH production upon administration of KEAf was investigated. The findings showed notable reduction in NAD<sup>+</sup>/NADH content in the aged skin vs skin of the young animals. Parallel to this, the NAD<sup>+</sup>/NADH level in the skin of old animals treated with KEAf was significantly higher than the skin tissue samples of their age-matched treated with PBS. There

**TABLE 2** Total collagen content evaluated by hydroxyproline

Mice skin tissue		Old mice skin tissue	
Young	Old	Vehicle	KEAf
Hydroxyproline (μg/0.1 g sample)			
294.19	189.5*	173.14	253.93**

\**P* < .05 vs. young skin connective tissue.

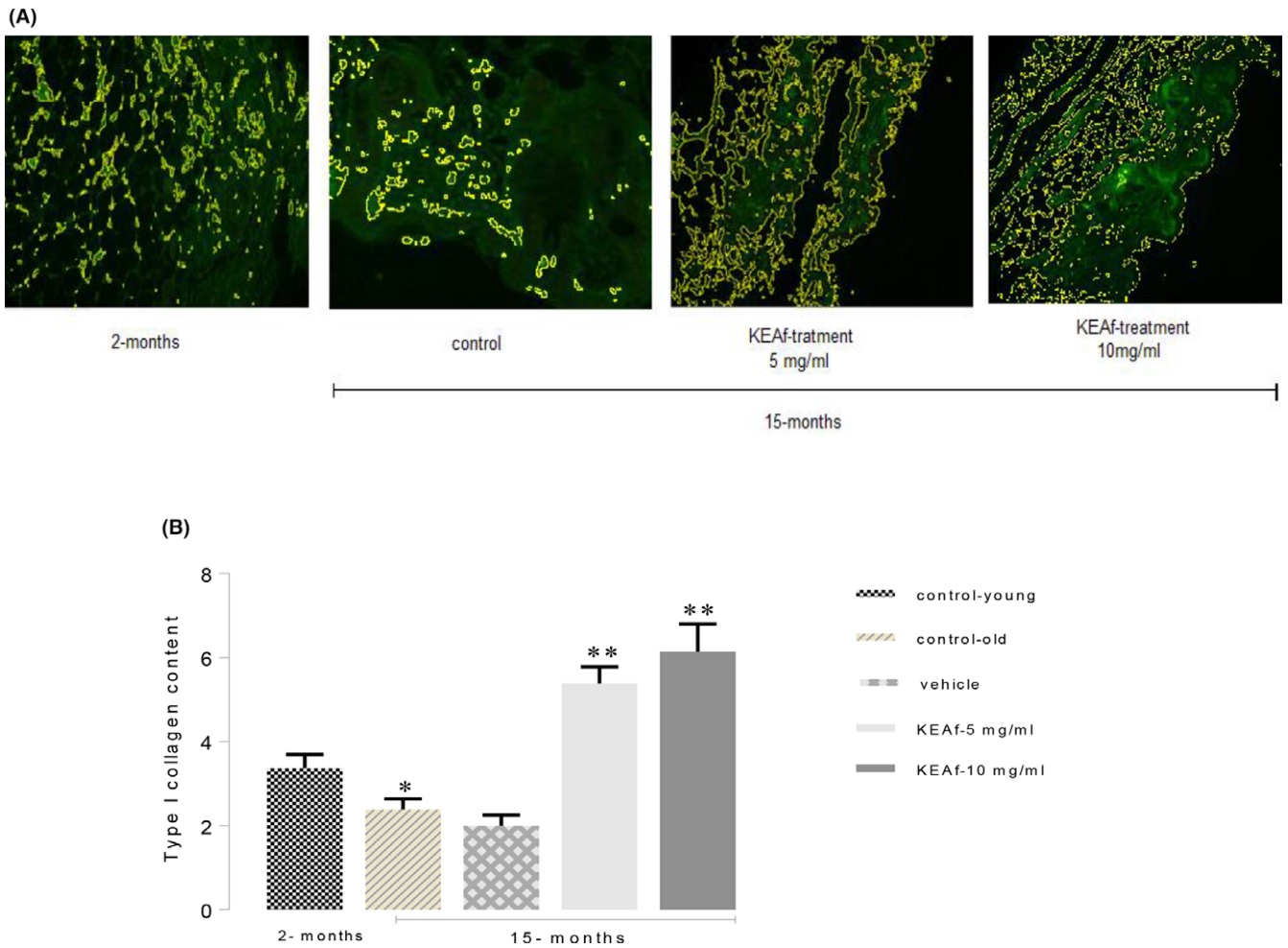
\*\**P* < .007 vs. vehicle.

was no difference in NAD<sup>+</sup>/NADH level between 5 and 10 mg/mL KEAf (*P* < .01, Figure 6).

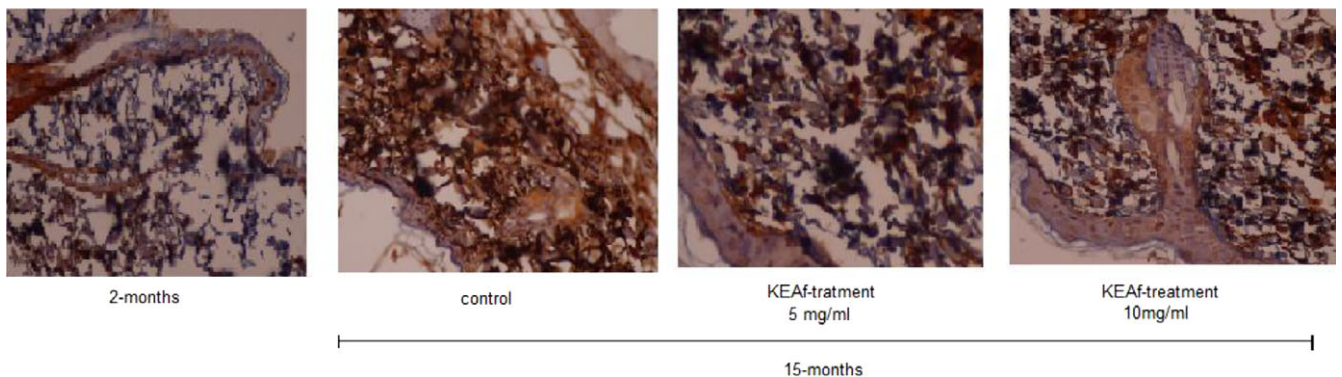
## 4 | DISCUSSION

The health benefits of KT have made some researchers consider it as a probiotic product.<sup>18</sup> During the fermentation process, effective components are formed and cause the beneficial properties of this drink. Antioxidant and free radical scavenging properties of KT, which are mainly attributed to flavonoid and polyphenols, are formed during fermentation.<sup>22,23</sup> The result of the present study indicated an increase in the flavonoid content of KT and especially KEAf in BT by about 21% and 38.7%, respectively, after fermentation of BT by Kombucha culture. The increase in the flavonoid content of KT and especially KEAf might be due to the secretion of some enzymes by the microbial biofilm that degrades the polyphenols to flavonoids.<sup>18</sup> Anti-inflammatory effects of flavonoids<sup>23,30</sup> are consistent with the lack of skin sensitization upon KEAf administration. Also, a large body of literature attributed anti-aging activities of flavonoids to their potent antioxidant properties.<sup>31,32</sup>

Histological comparison of the dermal sections between mice aged 15 months and 2 months revealed that increasing of age is associated by thinner fiber bundles, more open space within and between bundles in the dermis, fragmentation of collagen fibers, epidermal atrophy, and decreased numbers of fibroblasts. Previous



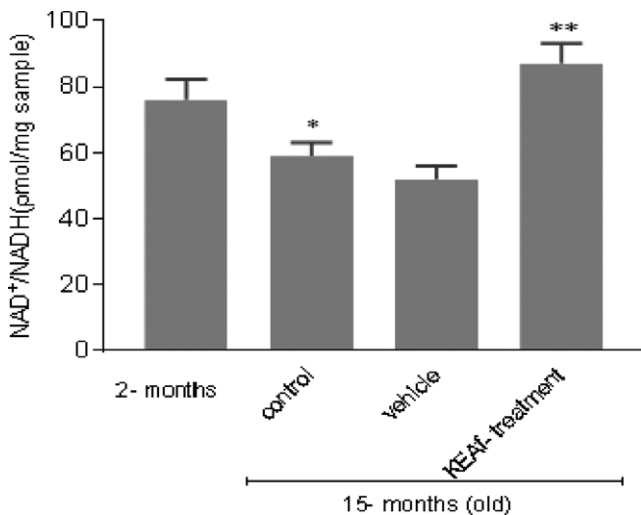
**FIGURE 4** (A) Immunostaining of the skin connective tissue from old and young animals with monoclonal antibody collagen type I revealed that type I collagen content decreased in aged skin, compared with younger mice skin. Intradermal treatment of skin of aged mice with KEAf revealed a significantly increased content of type I collagen (secondary antibody conjugate to FITC, magnification 200 $\times$ ). (B) Content of collagen type I was quantified for each image using the ImageJ analysis ([imagej.nih.gov/ij/](http://imagej.nih.gov/ij/)) in 4 nonconsecutive tissue sections (\* $P < .05$  vs. 2-mo-old mice, \*\* $P < .007$  vs. vehicle)



**FIGURE 5** Immunohistological evaluation of type III collagen in old mice skin aged 15 mo revealed prominent staining vs. 2 mo old (collagen fibers stained brown). This dermal staining was significantly increased in the skin of aged mice when treated with KEAf ( $n = 9$ , Scale bars = 100  $\mu\text{m}$ )

study showed that decreased numbers of keratinocytes in aged skin are largely responsible for the epidermal thinning.<sup>33</sup> Also, thinning of dermis in aged skin is due to reduction in the amount and

organization of connective tissue comprising febrile collagen bundles and elastic fibers along with a complex array of proteoglycan and other extra cellular matrix molecules.<sup>4</sup> The rate of such abnormalities



**FIGURE 6** NAD<sup>+</sup>/NADH ratio is measured by spectrophotometric assay. All KEAf-treated samples had significantly greater NAD<sup>+</sup>/NADH ratio compared with controls (N = 9, \*P < .05 vs. 2-mo-old mice, \*\*P < 0.01 vs. vehicle)

was significantly improved in aged mice skin treated with KEAf compared to the control groups. It suggests that these alterations in the dermal connective tissue are largely responsible for the thin, fragile, and finely wrinkled quality of naturally aged skin.<sup>4,8</sup>

Immunohistochemical evaluation of collagen type I in the skin of old subjects revealed a decrease in collagen type I by 29.3% compared with the young mice skin. Many studies have also demonstrated that collagen type I content decreases with age. However, there are differences in the collagen type I content of naturally aged skin,<sup>8</sup> sun protected skin,<sup>34</sup> and photo-aged skin.<sup>35</sup> As for type III collagen, there was no significant difference between skin of the old and young mice. This is consistent with previous studies indicating that type III collagen content does not change in covered skin with increasing age.<sup>36,37</sup> Nevertheless, other studies have shown that type III collagen decreases with age increment, although it is noteworthy that these researchers studied skin of a sun exposed site.<sup>35,38</sup> In addition, it should be considered that type III collagen constitutes a small portion of the total collagen in the skin,<sup>36</sup> and type I collagen is the main constituent of skin connective tissue by approximately 80% of skin wet weight.<sup>7</sup> Presumably, reduction in collagen content and declining trend in collagen fiber number and width with increasing age are consequences of destruction and impairment in the replacement of collagen type I. Treatment of aged mice skin with KEAf led to a measurable restoration of the dermal connective tissue abnormalities as a consequence of the natural aging process. KEAf could also significantly increase total collagen content of the skin and increase in the type I and III collagen content. This could be mainly attributed to flavonoid and polyphenols formed during fermentation causing antioxidant and free radical scavenging properties of KEAf.<sup>22,23,27</sup> In addition, Jayaban et al<sup>18</sup> reported that ethyl acetate fraction of KT contains dimethyl malonate and vitexin.

These compounds show strong radical scavenging activity with anti-aging properties.<sup>39,40</sup>

Alternatively, the present study demonstrated that ethyl acetate fraction of KT can stimulate energy production. Accordingly, the treatment of aged mice skin with KEAf significantly increased NAD<sup>+</sup>/NADH content whose level normally decreased in old mice. In parallel with these findings, a previous report demonstrated a correlation between NADPH levels and type I collagen expression in adult human skin fibroblast cell in culture. The type I collagen expression was decreased in parallel with decrease in NAD<sup>+</sup>/NADH level and increased with treatment with a complex of niacinamide.<sup>41</sup> Gomes et al. directly measured that during aging, decline in NAD<sup>+</sup> content inducing a pseudohypoxic state led to distribution of nuclear-mitochondrial communication and finally decline in mitochondrial function with age. They demonstrated that this phenomenon can be apparently reversible with adding NAD<sup>+</sup> derivatives to cell.<sup>42</sup> When there is a sufficient level of NAD<sup>+</sup>/NADH on fibroblasts, production of collagen is high.<sup>43</sup> Based on the findings of other studies and the finding presented in this study, it is hypothesized that the reduction in collagen content in aged animals occurs as a consequence of reduced NAD<sup>+</sup>/NADH level. Hence, it is hypothesized presumably that the beneficial effects of KEAf are due to flavonoids and energy-producing compounds such as great source of Vit B3, which can stimulate collagen production and repair abnormalities of connective tissue in naturally aged skin. Finally, the results of the current study suggest that KEAf treatment is useful to improve thickness and flexibility of aged skins. Accordingly, KEAf can be applied as a potential candidate for natural cosmeceuticals/functional cosmetics either used in this study or as a topically supplement in an attempt to prolong youthful skin appearance. However, more research is required to elucidate the mechanisms underlying this phenomenon and conduct an investigation on human skin.

Altogether, our results suggest that KEAf treatment is useful to improve thickness and flexibility of aged skin. The beneficial effects of KEAf are presumed to be due to flavonoids and energy-producing compound capable of repairing connective tissue in naturally aged skin. This study suggests KEAf as a potential candidate for natural cosmeceuticals/functional cosmetics and long-term use in aged populations. However, more research is required to elucidate the mechanisms beneath this phenomenon.

## ACKNOWLEDGMENTS

This work was financially supported by the Deputy of Research, Alborz University of Medical Sciences under reference No. 2427656.

## CONFLICT OF INTEREST

The authors have no conflict of interest.

## ORCID

Nafiseh Pakravan  <http://orcid.org/0000-0002-9355-1738>



## REFERENCES

- West MD, Pereira-Smith OM, Smith JR. Replicative senescence of human skin fibroblasts correlates with a loss of regulation and overexpression of collagenase activity. *Exp Cell Res.* 1989;184:138-147.
- Lavker R. Cutaneous aging: chronologic versus photoaging. *Photodermatol.* 1995;1:123-135.
- Glogau RG. Physiologic and structural changes associated with aging skin. *Dermatol Clin.* 1997;15:555-559.
- Varani J, Warner RL, Gharaee-Kermani M, et al. Vitamin A antagonizes decreased cell growth and elevated collagen-degrading matrix metalloproteinases and stimulates collagen accumulation in naturally aged human skin. *J Invest Dermatol.* 2000;114:480-486.
- Chung JH, Yano K, Lee MK, et al. Differential effects of photoaging vs intrinsic aging on the vascularization of human skin. *Arch Dermatol.* 2002;138:1437-1442.
- Yaar M. Clinical and histological features of intrinsic versus extrinsic skin aging. In: Gilchrist BA, Krutmann J, eds. *Skin Aging.* Berlin: Springer; 2006.
- Cheng W, Yan-hua R, Fang-gang N, Guo-an Z. The content and ratio of type I and III collagen in skin differ with age and injury. *Afr J Biotech.* 2011;10:2524-2529.
- Varani J, Dame MK, Rittie L, et al. Decreased collagen production in chronologically aged skin: roles of age-dependent alteration in fibroblast function and defective mechanical stimulation. *Am J Pathol.* 2006;168:1861-1868.
- Lee H-S, Kim M-R, Park Y, et al. Fermenting red ginseng enhances its safety and efficacy as a novel skin care anti-aging ingredient: in vitro and animal study. *J Med Food.* 2012;15:1015-1023.
- Mukherjee PK, Maity N, Nema NK, Sarkar BK. Bioactive compounds from natural resources against skin aging. *Phytomed.* 2011;19:64-73.
- Perricone NV. Treatment of skin damage using polyenylphosphatidylcholine. Google Patents; 2001.
- Yadav T, Mishra S, Das S, Aggarwal S, Rani V. Anticedants and natural prevention of environmental toxicants induced accelerated aging of skin. *Environ Toxicol Pharmacol.* 2015;39:384-391.
- Gould L, Abadir P, Brem H, et al. Chronic wound repair and healing in older adults: current status and future research. *Wound Rep Regen.* 2015;23:1-13.
- Katz SE. *Wild Fermentation: The Flavor, Nutrition, and Craft of Live-Culture Foods.* White River Junction, VT: Chelsea Green Publishing; 2016.
- Khan N, Mukhtar H. Tea and health: studies in humans. *Curr Pharm.* 2013;19:6141-6147.
- Lintner K. Cosmetic or dermatopharmaceutical compositions containing kombucha. Google Patents; 2008.
- Baumann LS. Less-known botanical cosmeceuticals. *Dermatol Ther.* 2007;20:330-342.
- Jayabalan R, Malbaśa RV, Lonćar LS, Vitas JS, Sathishkumar M. A review on Kombucha tea—microbiology, composition, fermentation, beneficial effects, toxicity, and tea fungus. *Comp Rev Food Sci Food Safety.* 2014;13:538-550.
- Jayabalan R, Chen PN, Hsieh YS, et al. Effect of solvent fractions of kombucha tea on viability and invasiveness of cancer cells—characterization of dimethyl 2-(2-hydroxy-2-methoxypropylidene) malonate and vitexin. *IJBT.* 2011;10:75-82.
- Jayabalan R, Marimuthu S, Swaminathan K. Changes in content of organic acids and tea polyphenols during kombucha tea fermentation. *Food Chem.* 2007;102:392-398.
- Sajilata M, Bajaj PR, Singhal R. Tea polyphenols as nutraceuticals. *Comp Rev Food Sci Food Safety.* 2008;7:229-254.
- Schagen SK, Zampeli VA, Makrantonaki E, Zouboulis CC. Discovering the link between nutrition and skin aging. *Dermato-Endocrinol.* 2012;4:298-307.
- Saeed N, Khan MR, Shabbir M. Antioxidant activity, total phenolic and total flavonoid contents of whole plant extracts *Torilis leptophylla* L. *BMC Complement Altern Med.* 2012;12:221.
- González S, Fernández-Lorente M, Gilaberte-Calzada Y. The latest on skin photoprotection. *Clin Dermatol.* 2008;26:614-626.
- Gao K, Henning SM, Niu Y, et al. The citrus flavonoid naringenin stimulates DNA repair in prostate cancer cells. *J Nut Biochem.* 2006;17:89-95.
- Srinivasan R, Smolinske S, Greenbaum D. Probable gastrointestinal toxicity of kombucha tea: is this beverage healthy or harmful? *J Gen Intern Med.* 1997;12:643-644.
- Meda A, Lamien CE, Romito M, Millogo J, Nacoulma OG. Determination of the total phenolic, flavonoid and proline contents in Burkina Faso honey, as well as their radical scavenging activity. *Food Chem.* 2005;91:571-577.
- Draize JH, Woodard G, Calvery HO. Methods for the study of irritation and toxicity of substances applied topically to the skin and mucous membranes. *J Pharmacol Exp Ther.* 1944;82:377-390.
- Kivirikko K, Liesmaa M. A colorimetric method for determination of hydroxyproline in tissue hydrolysates. *Scand J Clin Lab Invest.* 1959;11:128-133.
- Hämäläinen M, Nieminen R, Vuorela P, Heinonen M, Moilanen E. Anti-inflammatory effects of flavonoids: genistein, kaempferol, quercetin, and daidzein inhibit STAT-1 and NF-κB activations, whereas flavone, isorhamnetin, naringenin, and pelargonidin inhibit only NF-κB activation along with their inhibitory effect on iNOS expression and NO production in activated macrophages. *Mediat Inflamm.* 2007;2007:10 pp.
- Lamming DW, Ye L, Sabatini DM, Baur JA. Rapalogs and mTOR inhibitors as anti-aging therapeutics. *J Clin Lab Invest.* 2013;123:980-989.
- Amić D, Davidović-Amić D, Bešlo D, Trinajstić N. Structure-radical scavenging activity relationships of flavonoids. *Croat Chem Acta.* 2003;76:55-61.
- Masaki H. Role of antioxidants in the skin: anti-aging effects. *J Dermatol Sci.* 2010;58:85-90.
- Bernstein EF, Chen YQ, Kopp JB, et al. Long-term sun exposure alters the collagen of the papillary dermis: comparison of sun-protected and photoaged skin by Northern analysis, immunohistochemical staining, and confocal laser scanning microscopy. *J Am Acad Dermatol.* 1996;34:209-218.
- Sakai S, Yamanari M, Miyazawa A, et al. In vivo three-dimensional birefringence analysis shows collagen differences between young and old photo-aged human skin. *J Invest Dermatol.* 2008;128:1641-1647.
- Lovell C, Smolenski K, Duance V, Light N, Young S, Dyson M. Type I and III collagen content and fibre distribution in normal human skin during ageing. *Br J Dermatol.* 1987;117:419-428.
- Light ND. Estimation of types I and III collagens in whole tissue by quantitation of CNBr peptides on SDS-polyacrylamide gels. *BBA-Protein Struct Mol Enzym.* 1982;702:30-36.
- Wulf HC, Sandby-Møller J, Kobayasi T, Gniadecki R. Skin aging and natural photoprotection. *Micron.* 2004;35:185-191.
- Antonopoulou I, Varriale S, Topakas E, Rova U, Christakopoulos P, Faraco V. Enzymatic synthesis of bioactive compounds with high potential for cosmeceutical application. *App Microbiol Biotechnol.* 2016;100:6519-6543.
- Vina I, Semjonovs P, Linde R, Denija I. Current evidence on physiological activity and expected health effects of kombucha fermented beverage. *J Med Food.* 2014;17:179-188.

41. Osborne R, Carver R, Mullins L, Finlay D. Practical application of cellular bioenergetics to the care of aged skin. *Br J Dermatol*. 2013;169s2:32-38.
42. Gomes AP, Price NL, Ling AJ, et al. Declining NAD<sup>+</sup> induces a pseudohypoxic state disrupting nuclear-mitochondrial communication during aging. *Cell*. 2013;155:1624-1638.
43. Wagner S, Hussain M, Beckert S, et al. Lactate down-regulates cellular poly (ADP-ribose) formation in cultured human skin fibroblasts. *Eur J Clin Invest*. 2007;37:134-139.

**How to cite this article:** Pakravan N, Mahmoudi E, Hashemi S-A, et al. Cosmeceutical effect of ethyl acetate fraction of Kombucha tea by intradermal administration in the skin of aged mice. *J Cosmet Dermatol*. 2017;00:1-9.  
<https://doi.org/10.1111/jocd.12453>